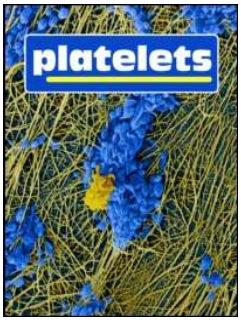

Platelets

ISSN: 0953-7104 (Print) 1369-1635 (Online) Journal homepage: http://www.tandfonline.com/loi/iplt20

Injectable-platelet rich fibrin using the low speed centrifugation concept improves cartilage regeneration when compared to platelet-rich plasma

Mustafa Abd El Raouf, Xuzhu Wang, Si Miusi, Jihua Chai, Abdel Basit Mohamed AbdEl-Aal, Mekkawy M. Nefissa Helmy, Shahram Ghanaati, Joseph Choukroun, Elisa Choukroun, Yufeng Zhang & Richard J Miron

To cite this article: Mustafa Abd El Raouf, Xuzhu Wang, Si Miusi, Jihua Chai, Abdel Basit Mohamed AbdEl-Aal, Mekkawy M. Nefissa Helmy, Shahram Ghanaati, Joseph Choukroun, Elisa Choukroun, Yufeng Zhang & Richard J Miron (2017): Injectable-platelet rich fibrin using the low speed centrifugation concept improves cartilage regeneration when compared to platelet-rich plasma, Platelets, DOI: 10.1080/09537104.2017.1401058

To link to this article: https://doi.org/10.1080/09537104.2017.1401058

View supplementary material

Published online: 14 Dec 2017.

Submit your article to this journal

View related articles

View Crossmark data

Full Terms & Conditions of access and use can be found at
http://www.tandfonline.com/action/journalInformation?journalCode=iplt20

Download by: [University Town Library of Shenzhen] **Date:** 14 December 2017, At: 20:50

http://www.tandfonline.com/iplt
ISSN: 0953-7104 (print), 1369-1635 (electronic)

platelets

Platelets, Early Online: 1–9
© 2017 Taylor & Francis. DOI: https://doi.org/10.1080/09537104.2017.1401058

Taylor & Francis
Taylor & Francis Group

Check for updates

Injectable-platelet rich fibrin using the low speed centrifugation concept improves cartilage regeneration when compared to platelet-rich plasma

Mustafa Abd El Raouf[1,2], Xuzhu Wang[1], Si Miusi[1], Jihua Chai[1], Abdel Basit Mohamed AbdEl-Aal[2], Mekkawy M. Nefissa Helmy[2], Shahram Ghanaati[3], Joseph Choukroun[3], Elisa Choukroun[4], Yufeng Zhang[1], & Richard J Miron[5]

[1]The State Key Laboratory Breeding Base of Basic Science of Stomatology (Hubei-MOST) and Key Laboratory of Oral Biomedicine Ministry of Education, School and Hospital of Stomatology, Wuhan University, Wuhan, China, [2]Faculty of Veterinary Medicine, Zagazig University, Egypt, [3]FORM, Frankfurt Oral Regenerative Medicine, Clinic for Maxillofacial and Plastic Surgery, Johann Wolfgang Goethe University, Frankfurt Am Main, Germany, [4]College of Dental Medicine, University of Nice, Nice, France, and [5]Department of Periodontology, School of Dental Medicine, University of Bern, Bern, Switzerland

Downloaded by [University Town Library of Shenzhen] at 20:50 14 December 2017

Abstract

The aim of the present study was to evaluate the effect of injectable platelet-rich fibrin (i-PRF) on cultivated chondrocytes and osteochondral regeneration in critical-sized osteochondral defect of the rabbit's knee in comparison to autologous platelet-rich plasma (PRP). Chondrocytes were first investigated for their ability to proliferate and differentiate in response to PRP and i-PRF. Thereafter, full-thickness critical-sized osteochondral defects 5 mm in diameter and 5 mm in depth were created in the knee joint of 12 adult female New Zealand White rabbits. Defects were regenerated with either PRP or i-PRF and compared to control. Animals were sacrificed at 4 and 12 weeks postoperatively and evaluated histologically by macroscopic and microscopic examination for cartilage regeneration. i-PRF significantly promoted chondrocyte proliferation and mRNA levels of Sox9, collagen type II, and aggrecan when compared to PRP and control. Histological analysis revealed that at 4 weeks, macroscopic ICRS scores from the i-PRF group were significantly enhanced when compared to the PRP and control groups. At 12 weeks post surgery, the microscopic ICRS scores demonstrated that the i-PRF group significantly improved cartilage regeneration when compared to PRP. In conclusion, the use of i-PRF using the low speed centrifugation concept significantly promoted chondrocyte activity and further improved cartilage regeneration when compared to PRP. The histological results revealed early and better cartilage regeneration within 4 weeks postoperatively when i-PRF was utilized and the results were maintained at 12 weeks. Future clinical studies are now needed investigating the regenerative potential of i-PRF in comparison to PRP for knee regeneration.

Keywords

Injectable PRF, knee regeneration, low speed centrifugation concept, platelet concentrates, platelet-rich fibrin, platelet-rich plasma

History

Received 9 August 2017
Revised 4 October 2017
Accepted 26 October 2017
Published online 11 December 2017

Introduction

Articular cartilage has a limited intrinsic ability for self-repair. Under physiological circumstances, injuries to the articular cartilage rarely heal spontaneously and usually result in further joint destruction and osteoarthritis [1–3]. One of the main reasons for this poor healing potential is due to the limited source of blood supply and its isolation from systemic regulation leading to hypocellularity [3]. Consequently, the aim of cartilage therapy procedures is to repair damaged joint surfaces with a functional tissue [4]. This however remains a challenge for orthopedic surgeons with no predictable means to fully regenerate lost or damaged tissues.

Over the last 20 years, several treatment strategies have been proposed for knee regeneration including autologous chondrocyte implantation (ACI) [5]. Other examples of treatments for cartilage lesions include bone marrow stimulation techniques, such as microfracture procedures that aim to recruit bone marrow elements to repair cartilage defects [6]. The results obtained for these treatment modalities however remain controversial with no ideal treatment modality for long-term success [1]. Often, these treatment strategies result in the formation of fibrocartilaginous tissue rather than normal articular cartilage. The repaired tissue therefore lacks the desired mechanical properties or zonal organization of the extracellular matrix (ECM) similar to those of the native articular cartilage and the biological and functional outcome of these treatments requires further improvements [7–9]. The ideal treatment modality should provide excellent repair fill with hyaline cartilage and maintain the quality of subchondral bone [10].

In an effort to improve the repair of osteochondral defects, biological products have seen increasing interest as an adjunct to surgical treatment and have also been utilized as a primary

Color versions of one or more of the figures in the article can be found online at www.tandfonline.com/iplt.

Correspondence: Richard Miron, University of Bern, Switzerland, Richard. E-mail: miron@zmk.unibe.ch
Yufeng Zhang University of Wuhan, China. E-mail: zyf@whu.edu.cn

Downloaded by [University Town Library of Shenzhen] at 20:50 14 December 2017

treatment modality [11,12]. One such biological product is platelet-rich plasma (PRP), which can easily be derived from autologous peripheral blood by centrifugation of whole blood yielding a 6 to 8 fold increase in growth factor concentration [13]. Platelet concentrates are rich in growth factors including platelet-derived growth factor (PDGF), transforming growth factor (TGF-b), vascular endothelial growth factor (VEGF), basic fibroblast growth factor (bFGF), and insulin-like growth factor (IGF) [13,14]. Furthermore, PRP has been shown to increase chondrocyte and mesenchymal stem cell proliferation, proteoglycan production, and type II collagen deposition [15,16].

One of the reported drawbacks of PRP is the additional use of anti-coagulants, known suppressors of wound healing. For these reasons, a second generation platelet concentrate termed platelet-rich fibrin (PRF) was developed to further improve wound healing in comparison to PRP [17]. Standard PRF contains a 3-dimensional fibrin matrix following centrifugation, however this is not ideal for knee regeneration where injection of PRP has been shown to be one of the gold standards due to its ease of use. Interestingly, the pioneering development of the low speed centrifugation concept introduced the development of a new formulation of PRF whereby a liquid formulation of PRF could be obtained for injectable purposes (i-PRF) without using anti-coagulants [18–20]. This new platelet concentrate does not contain any anti-coagulants, maintains a liquid viscosity for roughly 15 minutes following centrifugation and interestingly can be injected in a similar method to PRP yet bears the added advantage of forming a fibrin clot shortly after injection. Therefore, the purpose of this study was to evaluate the effect of i-PRF on chondral tissue regeneration. The first aim of the study was to compare the effect of i-PRF and PRP on cultured chondrocytes *in vitro*. The secondary aim was to compare the efficacy of i-PRF and PRP on regeneration of critical-sized osteochondral defects in the rabbit's knee.

Materials and methods

Preparation of PRP and i-PRF

Five adult rabbits were used to isolate PRP and i-PRF. For PRP, 10 mL of whole blood treated with anticoagulant (sodium citrate) was centrifuged at 900 × g for 5 min to separate the plasma from hemocyte (erythrocyte and leukocyte) fractions and then the plasma was centrifuged a second time at 2000 × g for 15 min to separate PRP from platelet-poor plasma (PPP) [21]. In total, 1 mL of PRP was isolated from 10 mL of whole blood. The i-PRF was produced as follows: 10 mL of whole blood without anticoagulant was immediately centrifuged at 700 rpm for 3 min (60g force) with Choukroun PRF Duo Centrifuge (Process for PRF, Nice, France). The 1 mL upper plasma layer was then collected and designated as i-PRF. The collected PRP and i-PRF were then transferred to 6-well in vitro plastic culture dishes with 5 mL of culture media (Dulbecco's Modified Eagle Medium (DMEM); HyClone, Thermo Fisher Scientific Inc., Beijing, China) and processed as further described.

Isolation of chondrocytes

Pieces of cartilage from the femoral condyle of an adult rabbit was collected and washed three times with phosphate buffered saline (PBS; pH 7.2) containing 1% antibiotics and cut into small pieces with sterilized surgical scissors. The cartilage tissue pieces were then transferred into T25 tissue culture flasks containing minimal DMEM and allowed to adhere for 2 h. Then, 3 mL of DMEM containing 20% fetal bovine serum (FBS; Gibco, Australia) and antibiotics was added. After one week when cells reached confluency, cells were trypsinized and cultured in DMEM with 10% FBS. Chondrocytes used for experiments were chosen from passages 3–7.

Cell culture

Platelet concentrates including PRP and i-PRF were incubated for three days in a humidified 5% CO2 atmosphere at 37°C and thereafter conditioned media was collected and utilized in future experiments as 20% of the total volume as previously described [22]. Chondrocytes were detached from tissue culture plastic using trypsin (HyClone) prior to reaching confluency. Cells were cultured in a humidified atmosphere at 37°C in growth medium consisting of DMEM, 10% FBS and 1% antibiotics.

The effects of PRP and i-PRF on chondrocytes proliferation

The effects of PRP and i-PRF on the proliferation of chondrocytes were determined by the Cell Counting Kit-8 (Dojindo, Japan) at time points 1, 3 and 5 days and measured by a microplate reader scanning at 450 nm (PowerWave XS2, BioTek, Winooski, VT, USA) as previously described [23].

The effects of PRP and i-PRF on chondrogenesis-related genes expression

Real-time PCR was used to investigate the effects of PRP and i-PRF on chondrogenesis-related genes expression. Chondrocytes were cultured with PRP or i-PRF in 24-well plates. After seven days of culture, total RNA was extracted from the cultured cells using AxyPrep™ Multisource Total RNA Miniprep Kit (AXYGEN, Union City, CA, USA) according to the manufacturer's instructions. The RNA concentration was determined by a NanoDrop 2000 UV-Vis Spectrophotometer as previously described [24]. A total of 1 μg RNA solution was converted to complementary DNA using a First Strand cDNA Synthesis Kit (GeneCopoeia, Rockville, MD, USA) to a final volume of 100 μL. The sequences of primers for SOX9, collagen type II alpha 1 (COL2A1), aggrecan (ACAN) and glyceraldehyde 3-phosphate dehydrogenase (GAPDH) genes of rabbits are listed in Supplemental Table 1. The ΔΔCt method was used to calculate gene expression levels relative to house-keeping gene GAPDH and normalized to control cells.

The effects of PRP and i-PRF on cartilage regeneration in an inflammatory environment induced by il-1β

Chondrocytes were cultured in the presence of IL-1β to mimic an osteoarthritic environment. Briefly, chondrocytes were cultured with or without 10ng/mL IL-1β and the addition of PRP and i-PRF for 48 hours, and then total RNA was isolated from chondrocytes for detection of the expression of SOX9, COL2A1, ACAN, a disintegrin and metalloproteinase with thrombospondin motifs 4 (ADAMTS4), prostaglandin-endoperoxide synthase 2 (PTGS2) and matrix metalloproteinase 13 (MMP13) genes using RT-PCR as previously described. GAPDH was used as a house keeping gene.

Statistical analysis for in vitro study

Statistical analysis was performed by one-way ANOVA using Graphpad Software v.6 (Graphpad Software, La Jolla, CA, USA). Statistical significance was set at $p < 0.05$. All data are expressed as the mean ± SE. All in vitro experiments were performed in triplicate with three independent experiments.

Animals and surgical procedure

A total of 12 adult female New Zealand White (NZW) rabbits (weighing 2.5 – 3.0 Kg) were used in this study. Prior to the start

Downloaded by [University Town Library of Shenzhen] at 20:50 14 December 2017

of the experiments, animal handling and surgical protocols were conducted according to the guidelines for animal care and use committee of Wuhan University, People's Republic of China, and approved by the Ethics Committee at the School of Dentistry. This animal study also followed the ARRIVE guidelines for animal research. All rabbits were first allowed to acclimate to the facility for one week prior to the surgery. They were fed in separate cages in a temperature-controlled room with free access to antibiotic-free food and water. The animals were divided into three groups including 1) control group, 2) PRP group, and 3) i-PRF group.

The rabbits were generally anesthetized with intraperitoneal injection of chloral hydrate (10%, 4 mL/kg body weight) and were placed in a supine position. Antibiotic prophylaxis was given 30 min prior to surgery [25]. Following shaving and standard sterile preparation of both lower extremities, the surgical technique was performed bilaterally (right and left knees). The knee joint was opened through medial para-patellar approach [10]. A 4 cm medial para-patellar arthrotomy was performed and the patella was dislocated laterally to expose the surface of femoro-patellar groove. The joint was then carefully inspected to ascertain whether any pre-existing cartilage pathology was present.

A full-thickness defect of 5 mm in diameter and 5 mm in depth was created through the articular cartilage and subchondral bone in the center of the patellar groove in rabbits of each group by using a drill-equipped with a 5 mm bur. The defects were then debrided of any remaining osseous or cartilage fragments and were irrigated with 0.9% sterile saline solution. In group I, the defects were left untreated (control group, $n = 4$). In group II, the defects were filled with 1 mL of PRP only (PRP group, $n = 4$). In group III, the defects were filled with 1 mL of i-PRF (i-PRF group, $n = 4$).

The wound was closed in two layers with interrupted pattern. Prior to concluding the surgical procedure, the knee was moved through a full range of motion to ensure that normal patellar tracking occurred. All the rabbits were given penicillin (15 mg/kg body weight) for 3 days post-operation. The animals were housed individually in standard rabbit cages and allowed to free movement without joint immobilization.

Animals were sacrificed at 4 and 12 weeks post-operatively with an overdose of anesthesia. The samples were examined for gross and histopathological examinations. The size of the samples was four for each group at each time point.

Macroscopic morphology

At necropsy, the distal parts of the femurs were excised, photographed and graded for cartilage repair, according to the International Cartilage Repair Society (ICRS) macroscopic scoring system on a scale from 0 to 12 (Supplemental Table 2) as previously described [25].

Histological examination

After macroscopic evaluation, the samples were fixed in 4% formaldehyde for 7 days, decalcified in 10% ethylene diamine tetraacetic acid (EDTA) for 4 weeks at room temperature, dehydrated in a series of alcohol from 70% to 95% and then embedded in paraffin wax. After embedding, the samples were cut into 5 μm sections. Then, the sections were stained with hematoxylin and eosin for ICRS histological scoring and Safranin O/fast green to assess glycosaminoglycan content. The ICRS histological score is graded on a scale of 0 to 18 (Supplemental Table 3) [26].

Statistical analysis for in vivo study

All the results were reported as mean ± standard deviations. A one-way ANOVA was used to carry out statistical analysis. $p \leq 0.05$ was considered as statistically significant. All the values were analyzed using the SPSS software (version 20.0; IBM, America).

Results

Chondrocytes proliferation

At 1 day post seeding, no significant difference was observed in chondrocyte numbers between all groups, regardless of the presence of PRP and i-PRF. However, at 3, 5 and 7 days post-seeding, it was found that both PRP and i-PRF significantly increased the proliferation rates of chondrocytes in comparison to control tissue culture plastic. Furthermore, i-PRF was significantly higher than PRP at 5 and 7 days (Figure 1).

Chondrogenesis-related genes expression

The mRNA levels of chondrogenesis-related genes SOX9, Col2A1 and ACAN were evaluated by real-time PCR. It was found that both PRP and i-PRF increased the expression of SOX9, COL2A1 and ACAN at 7 days when compared to controls with i-PRF demonstrating the highest expression of these three genes (Figure 2).

The effects of PRP and i-prf on cartilage regeneration in an inflammatory environment induced by il-1β

IL-1β was utilized to simulate an osteoarthritic condition. It was found that Il-1β inhibited the expression of SOX9, COL2A1 and ACAN in chondrocytes, while it increased expression of ADAMTS4 and PTGS2. Compared to the IL-1β group, the addition of PRP and i-PRF upregulated the expression levels of pro-regenerative genes including SOX9, COL2A1 and ACAN and downregulated the expression levels of ADAMTS4, PTGS2 and MMP13. Furthermore, i-PRF demonstrated the highest expression of SOX9, COL2A1 and ACAN and the lowest expression of ADAMTS4 and PTGS2 (Figure 3).

Macroscopic observation of the cartilage defects

The regenerated osteochondral defect areas of all groups were examined macroscopically at the 4th and 12th week following surgery (Figure 4). At 4 weeks, the macroscopic appearance of the treated defects in the i-PRF group revealed nearly complete

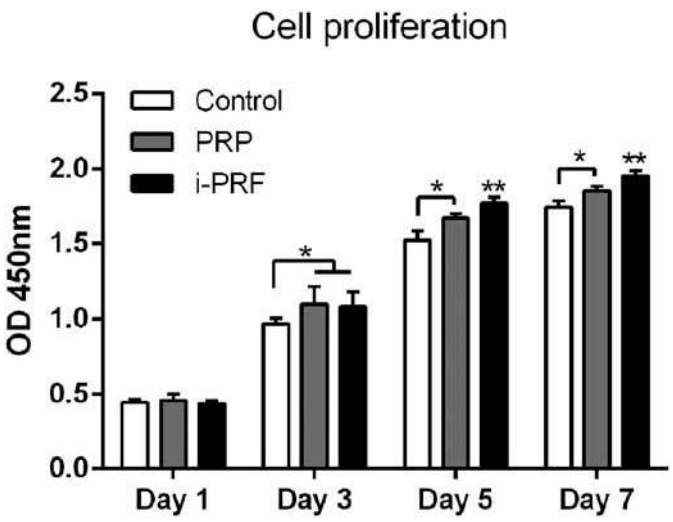

Figure 1. Effects of PRP and i-PRF on the proliferation of rabbit chondrocytes at 1, 3 and 5 days. (* denotes significant difference between two groups $p < 0.05$, ** denotes significantly higher than all other treatment groups $p < 0.05$). Assay performed in triplicate with 3 independent experiments.

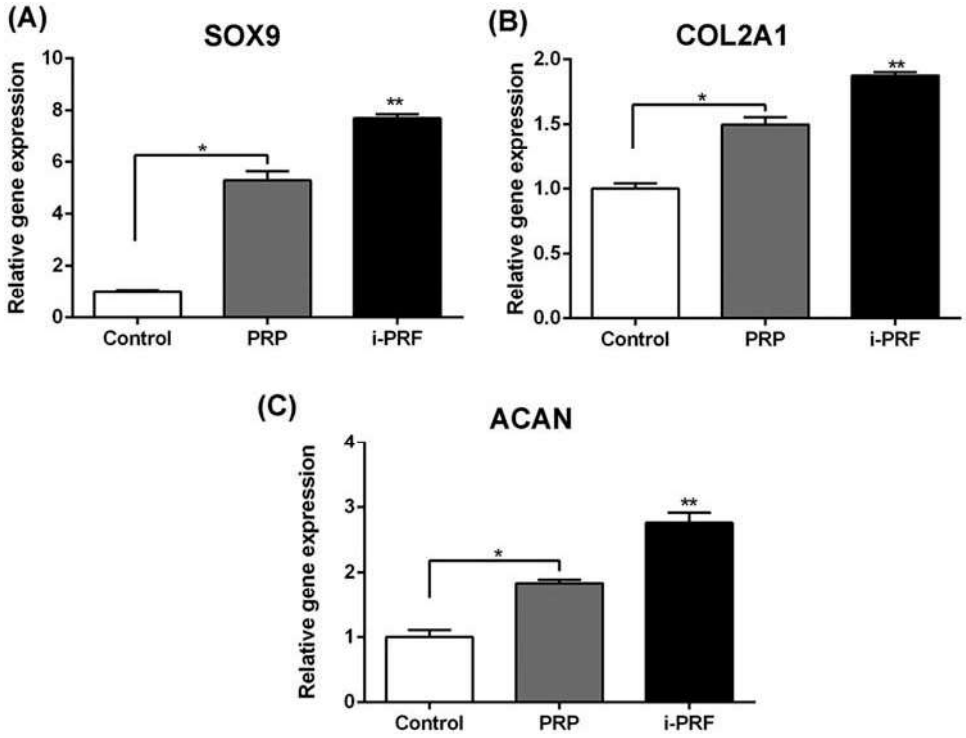

Figure 2. The effect of PRP and i-PRF on the expression of regeneration-related and ECM-related genes at 7 days (A) SOX9; (B) COL2A1; and (C) ACAN. (* denotes significant difference between two groups $p < 0.05$, ** denotes significantly higher than all other treatment groups, $p < 0.05$). Assay performed in triplicate with 3 independent experiments.

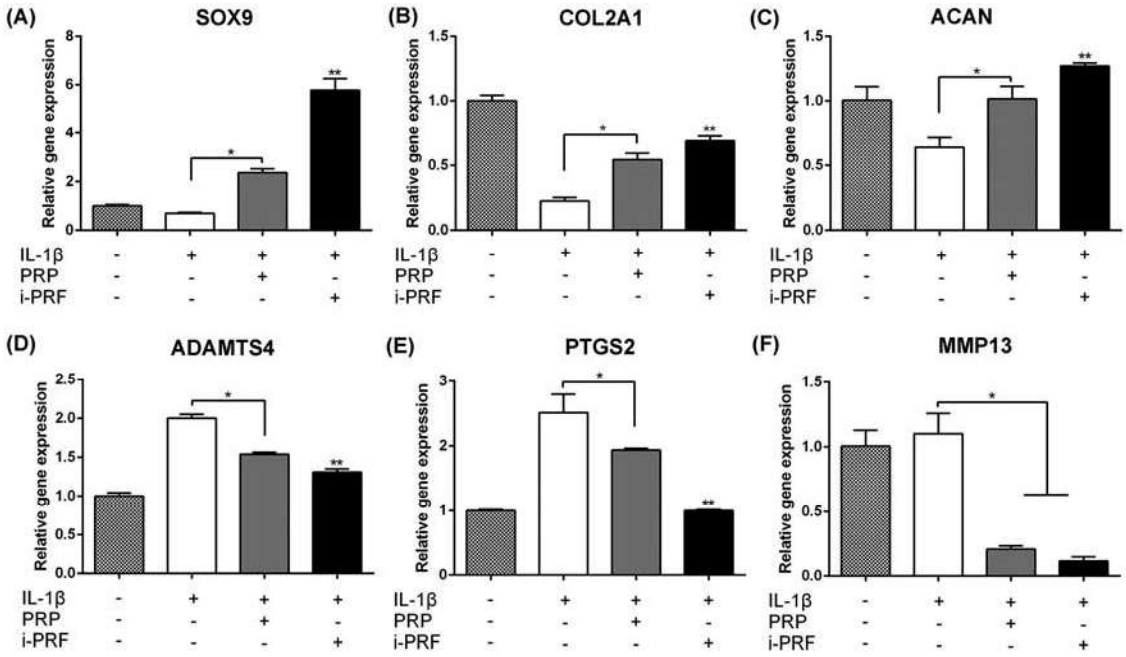

Figure 3. The effect of PRP and i-PRF on the expression of regeneration-related and ECM-related genes at 7 days with and without IL-1β (A) SOX9; (B) COL2A1; (C) ACAN; (D) ADAMTS4; (E) PTGS2 and (F) MMP13. (* denotes significant difference between two groups $p < 0.05$, ** denotes significantly higher/lower than all other treatment groups with IL-1β, $p < 0.05$). Assay performed in triplicate with 3 independent experiments.

healing with white opaque tissue and good integration with the surrounding healthy cartilage tissue (Figure 4). The PRP and control-treated groups showed white and reddish opaque, patchy tissues without integration to the surrounding healthy cartilage tissue when compared to the i-PRF group (Figure 4A, B & C). The ICRS score of the control group was significantly lower than the PRP and i-PRF groups, while the ICRS score of the i-PRF group was significantly higher than the PRP group ($p < 0.05$) (Figure 5a). At 12 weeks, the macroscopic appearance showed no significant difference between all groups and all demonstrated a smooth surface and good integration to the surrounding healthy cartilage tissue (Figure 4D, E & F). No significant differences in the ICRS scores were observed ($p < 0.05$) (Figure 5b).

Downloaded by [University Town Library of Shenzhen] at 20:50 14 December 2017

Downloaded by [University Town Library of Shenzhen] at 20:50 14 December 2017

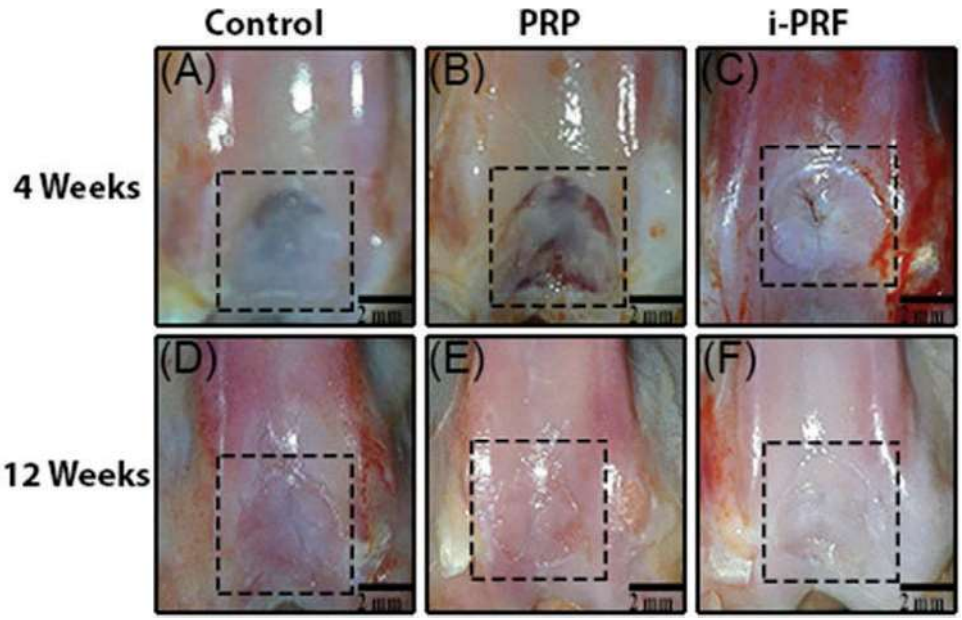

Figure 4. Macroscopic appearance of the osteochondral defects at 4 and 12 weeks post-operatively in the control group (A & D), PRP group (B & E), and i-PRF group (C & F).

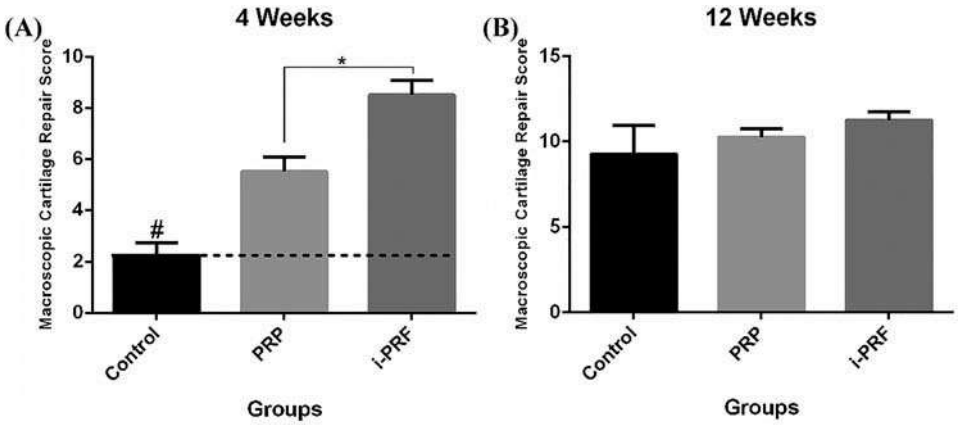

Figure 5. Total ICRS Macroscopic scores of the regenerated osteochondral defects in the trochlear groove at 4 weeks (A) and 12 weeks (B) post-operatively. Data are represented as mean ± SD. #: significantly lower than PRP and i-PRF groups; $p < 0.05$.

Microscopic observation of the cartilage defects

The regenerated areas of the osteochondral defects of all groups were evaluated microscopically by H & E staining and Safranin O staining at 4 and 12 weeks postoperatively. At 4 weeks, the microscopic appearance of the treated defects in the i-PRF group (Figure 6c & f) (Figure 7c & f) revealed complete repair of the cartilage defect with hyaline tissue (positively stained with Safranin O staining), a smooth surface and normal thickness of the adjacent healthy cartilage tissue. It was also observed that better integration of the repaired tissue with surrounding articular cartilage was visualized. In addition, the repaired tissue showed clusters of large round cells rich in cytoplasm (chondrocytes-like cells). The subchondral bone in the i-PRF treated group was also regenerated under the repaired cartilage tissue and increased bone remodeling. The PRP treated group and the control group showed complete filling of the defect with proteoglycan-rich tissue positive for Safranin O staining with increased remodeling of the subchondral bone (fibro-cartilage-like tissue rather than bone tissue) (Figure 6a, b, d & e) (Figure 7a, b, d & e). The repaired tissue showed either scattered single or isogenous groups of fairly large round cells rich in cytoplasm. The ICRS score at 4 weeks demonstrated that the i-PRF group was significantly higher than the PRP and control groups ($p < 0.05$) (Figure 8a). At 12 weeks, the microscopic appearance of the treated defect in the i-PRF group (Figure 6i & l) (Figure 7i & l) showed complete regeneration of the cartilage and subchondral bone areas with complete integration to the adjacent normal tissues and normal chondrocytes. In the PRP and control groups, the cartilage defect revealed slightly less than complete regeneration with good integration to the adjacent healthy cartilage tissue only after 12 weeks (Figure 6g, h, j & k) (Figure 7g, h, j & k). The subchondral bone in both the PRP and control groups showed incomplete regeneration with remaining bone defects. The ICRS score of the control group was significantly lower than the i-PRF and PRP groups, while the i-PRF group was significantly higher than the PRP group ($p < 0.05$) (Figure 8b).

Discussion

Cartilage injury and repair remains a major clinical challenge despite advances made in surgical techniques and procedures.

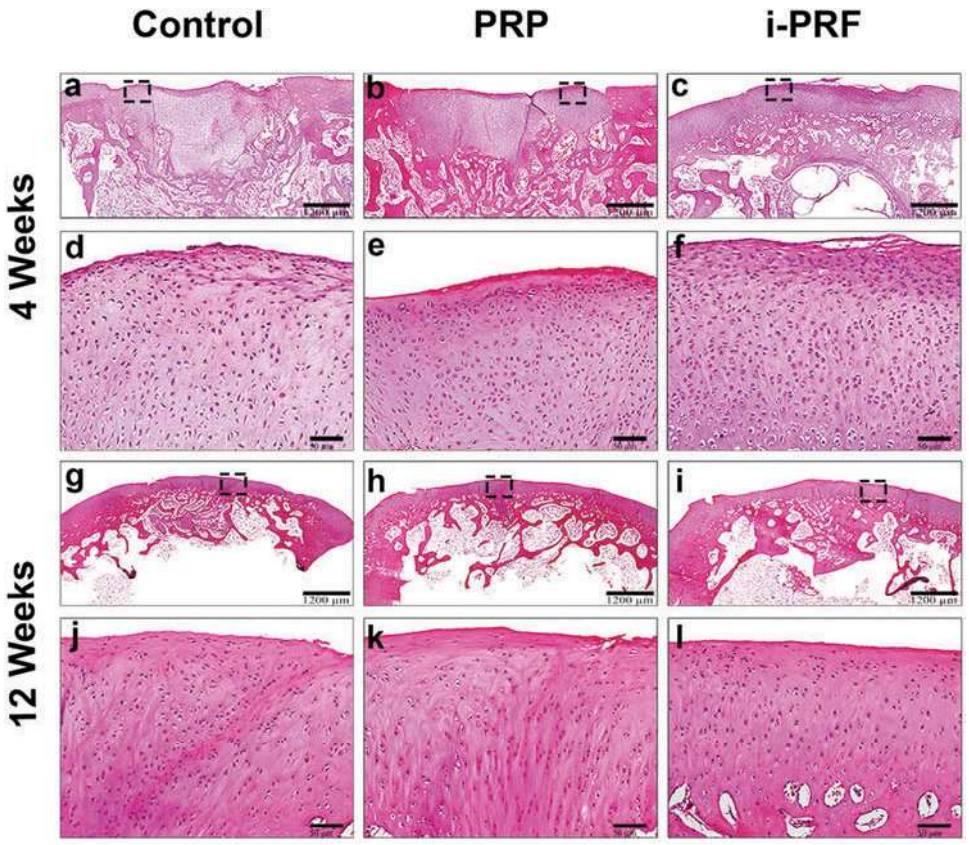

Figure 6. Histological appearance of H & E staining of the regenerated osteochondral defects in the trochlear groove at 4 weeks (a – f) and 12 weeks (g – l).

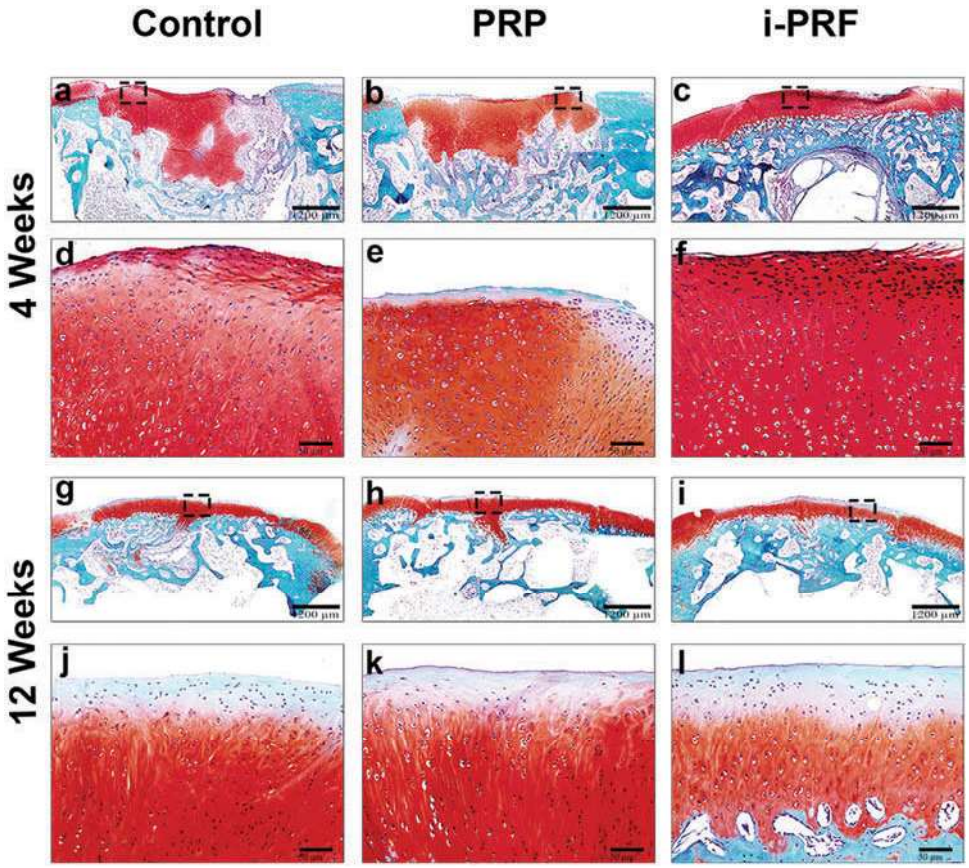

Figure 7. Histological appearance of safranin O staining of the regenerated osteochondral defects in the trochlear groove at 4 weeks (a – f) and 12 weeks (g – l).

Downloaded by [University Town Library of Shenzhen] at 20:50 14 December 2017

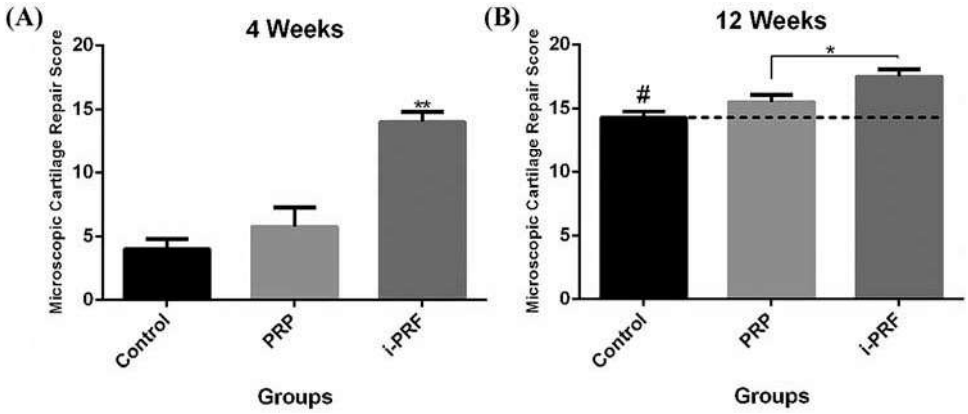

Figure 8. Total ICRS Microscopic scores of the regenerated osteochondral defects in the trochlear groove at 4 weeks (A) and 12 weeks (B) post-operatively. Data are represented as mean ± SD. **: significantly higher than the control and PRP groups; #: significantly lower than PRP and i-PRF groups; $p < 0.05$.

Downloaded by [University Town Library of Shenzhen] at 20:50 14 December 2017

Recently, much effort has been directed to enhance the potential for cartilage to heal via natural processes [27]. The present study aimed to investigate for the first time the effect of a novel injectable PRF modality (i-PRF) on cartilage repair in critical-sized osteochondral defects in a rabbit model in comparison to the frequently utilized PRP.

Over the past decade, PRP has been used as a gold standard for tissue regeneration of the knee as it serves as a source of autologous growth factors, and has gained wide acceptance in several surgical applications such as bone regeneration in orthopedic surgery, periodontal and maxillofacial surgery, otolaryngology, and plastic surgery [28,29]. PRP has the ability to release endogenous growth factors that play a significant role in the tissue repair process especially those with low vascularization and cellular density [30].

Nevertheless, while PRP remains a gold standard for minimally-invasive surgery for athletes and the elderly, the results investigating chondral tissue repair have been controversial [31,32] and many believe this may be attributed to the various compositions of PRP fractions of plasma [32]. Wu et al. in 2007 reported that the ability for cartilage formation within PRP scaffolds was enhanced when PRP was used as a carrier system for cultured autologous chondrocytes in a rabbit model [33]. In a study by Qi et al. in 2009, autologous PRP demonstrated that PRP improved collagen matrix synthesis and stimulated cartilage formation in larger cartilage defects that required osteochondral grafts or autologous chondrocytes implantation [10]. In another study by Lee et al. in 2013, it was suggested that the repair of the osteochondral defects of the rabbits' knee can be facilitated by transplantation of PRP gel with synovial membrane derived mesenchymal stem cells (SDSCs) [1]. Lastly, it was previously reported that growth factors in PRP are considered as a therapeutic possibility for enhancing chondral repair to treat the degenerated osteoarthritic knees in their early stages [13].

Interestingly, numerous advancements have been made with respect to platelet concentrates over the past decade. PRF is a platelet concentrate that forms a 3-dimensional matrix containing all the cellular and molecular elements needed for tissue repair [34]. It contains a higher concentration of blood derived growth factors yet is easier to produce with less time required for centrifugation and no additives [35]. The PRF matrix has the ability to trap circulating cytokines [36], and therefore their lifespan is increased which improves their usage in the primary stages of matrix remodeling. The additional use of PRF to BM-MSCs transplants in an osteochondral defect study by Haleem et al. in 2010 found that PRF significantly improved functional scores of the knee joint within 6 months and as assessed by MRI [37].

While PRF has been used as a 3-dimensional scaffold, it was recently shown that lower centrifugation speeds and time affect growth factor release and cell bioactivity of PRF-based matrices [18–20,22]. High centrifugation speeds tend to push cells toward the bottom of the centrifugation tubes and away from the PRF matrix clot collected in the upper layer [17]. Therefore, a reduction in G-force has been shown to optimize PRF [17]. Nevertheless, PRF contains a 3-dimensional fibrin matrix, not necessarily ideal for knee regeneration where injection of PRP has been shown to be a gold standard for minimally invasive procedures. Interestingly, a new injectable liquid formulation of PRF (i-PRF) has been developed by further lowering centrifugation speeds (60 g force for 3 minutes) whereby i-PRF can be utilized for injectable purposes. This differs significantly in G-forces to produce platelet concentrates as previous formulations of PRP utilize a 2000 g-force. This new platelet concentrate does not contain any anti-coagulants, maintains a liquid viscosity for roughly 15 minutes and interestingly forms a fibrin clot within the knee following injection. Therefore, it possesses many ideal properties for chondral regeneration.

PRP and i-PRF have many advantages over products derived from animal origins and recombinant growth factors as they do not create an immunological reaction or carcinogenic effects, and the cost of using such therapies is considerably lower. In addition, i-PRF has additional advantages when compared to PRP in that i-PRF is produced with a single centrifugation protocol and contains a higher concentration of leukocytes. In the present study, we investigated for the first time the regenerative potential of i-PRF as a potential platelet concentrate for cartilage regeneration.

The results demonstrated that i-PRF had a significantly positive effect on osteochondral formation as shown by histological analysis (Figures 6 & 7). The present study was also confirmed with the recently introduced concept by Evans et al. 2007 known to facilitate endogenous cartilage repair using molecular stimuli to initiate the reparative process in situ [38]. It is known that a full-thickness cartilage defect more than 3 mm have no ability to heal spontaneously [39]. In the present study, the standard size of 5 mm diameter X 5 mm depth was chosen and the defects were treated with PRP, i-PRF, or left empty. Interestingly, autologous i-PRF initiated and enhanced a rapid and complete cartilage repair significantly faster than PRP. The results showed that i-PRF exhibited its superiority at 4 and 12 weeks post-surgery and played a positive role in the reparative process of cartilage defects. This may be attributed to the increased concentration of platelets, leukocytes and growth factors that initiates the

Downloaded by [University Town Library of Shenzhen] at 20:50 14 December 2017

migration and proliferation of chondroblasts and BMSCs at early stages of cartilage regeneration [10]. Noteworthily, in the present study, the defects were created in a young rabbit animal model. In humans, osteoarthritis is a long-term chronic disease that affects millions of people worldwide. Human pathological defects are clearly harder to regenerate than those created in the present study absent of systematic inflammation. Therefore, the significant increase in regeneration as found in the present study with i-PRF is likely to further promote hard-to-heal human cartilage defects in the elderly. Future clinical studies are however needed to confirm this hypothesis.

In a previous study by Qi et al. in 2009, it was demonstrated that repaired cartilage at the edges of the defects was better than that at the central region of the defect (the neo-cartilage tissue was formed from the edges of native cartilage to the center of the defect without bridging the defects). The authors attributed that this may be due to the migration potential of chondrocytes from the nearby native cartilage [10]. The present study was in agreement with these findings. It was recently shown in various cell culture models that i-PRF significantly promoted better recruitment of various cells when compared to PRP [20,21,40]. Therefore, it was anticipated that i-PRF could more evenly regenerate cartilage in the present study as a result of its increased ability to recruit cells toward defective tissues. The present study also confirmed our hypothesis that the early repair of subchondral bone with i-PRF had a positive effect on the repaired cartilage tissue at earlier time points.

One remaining aspect left to investigate is the role of incorporating leucocytes into platelet concentrates. The impact of leukocytes within platelet formulations has been debated not only in the cartilage regenerative field but also in other fields including soft tissue regeneration as well as bone regeneration. Several groups have therefore performed experiments to investigate the direct role of leukocytes into various platelet concentrates. In the bone regenerative field, three separate studies performed by independent groups investigated the regenerative potential of PRP with or without leukocytes. In each of these studies, a significant improvement in the regenerative potential of PRP was observed when leukocytes were added [41–43].

In the cartilage field, little data is available specifically investigating the direct role of white blood cells/leukocytes in platelet-induced regeneration. To the best of the authors knowledge, most of the studies are inconclusive or do not directly investigate the role of leukocytes specifically via knockdown or knockin models. Our group has however investigated in a series of studies, the in vitro impact of addition of leukocytes on cellular behavior and growth factor release. In these studies it was found that a higher leukocyte number favored more growth factor release and tissue wound healing [22,44]. With respect to the two modalities utilized in this study (PRP and i-PRF), our group has recently performed 3 in vitro studies comparing the liquid injectable PRF (high concentration of leukocytes) directly to PRP (low concentration of leukocytes) [20,21,40]. In each of these studies, the i-PRF generated more favorable results and it was hypothesized that the incorporation of leukocytes played a major role as the concentration of growth factors between i-PRF and PRP was very similar. Therefore, it is believed that the better wound healing properties of i-PRF have to do with A) anti-coagulant removal and/or B) incorporation of leukocytes [20,21,40]. Nevertheless, much further research is necessary to determine the beneficial role of leukocytes during cartilage repair.

Conclusion

The results from the present study demonstrated for the first time the superior cartilage regeneration potential of i-PRF using the low speed centrifugation concept in the early stages of cartilage repair. While it was found that PRP improved the osteochondral repair process by 12 weeks, the results obtained with i-PRF were significantly superior as early as 4 weeks post-surgery. In conclusion, it was found that autologous i-PRF improved the subchondral bone plate in the early stages of cartilage regeneration in as little as 4 weeks post-surgery. Further large animal studies and human clinical trials are now needed to further investigate the chondral repair potential of i-PRF.

Author contributions

MAER, XW, and SM performed the experiments. ABMA, NHMK, SG, JC, EC, YZ, and RJM designed the experiments. MAER, XW, SM, YZ, and RJM wrote the manuscript. All authors revised the manuscript. All authors approve the final submission of this article.

Conflict of interest

Joseph Choukroun is the inventor of PRF and is a stockholder in Process for PRF. All other authors declare no conflict of interest.

Funding

This work was supported by the funds of the National Natural Science Foundation of China (81271108 and 81570954 to Yufeng Zhang), the Fundamental Research Funds for the Central Universities (410500041), and Process for PRF, France.

Role of the funding source

The National Natural Science Foundation of China provided grants to YZ that helped contribute to the material reagents and animals utilized in this study. Process for PRF provided the centrifuge and tubes utilized in this study and additional funds to conduct this study.

Supplemental data

Supplemental data for this article can be accessed here

References

[1] Lee JC, Min HJ, Park HJ, Lee S, Seong SC, Lee MC. Synovial membrane-derived mesenchymal stem cells supported by platelet-rich plasma can repair osteochondral defects in a rabbit model. Arthroscopy 2013;29(6):1034–1046.
[2] Hunziker EB. Articular cartilage repair: basic science and clinical progress. A review of the current status and prospects. Osteoarthritis Cartilage 2002;10(6):432–463.
[3] Buckwalter JAMH. Articular cartilage repair and transplantation. Arthritis Rheum 1998;41(8):1331–1342.
[4] Khan IMRS, Williams R, Dowthwaite GP, Oldfield SF, et al. The development of synovial joints. Curr Top Dev Biol 2007;79:1–36.
[5] Brittberg M, et al. Treatment of deep cartilage defects in the knee with autologous chondrocyte transplantation. N Engl J Med Sci (Paris) 1994;331:889.
[6] Steadman JR, Cole BJ, Kercher JS, Rodkey WG, Briggs KK. Microfracture. Cartilage 2010;1(2):78–86.
[7] De Vries-Van Melle ML, Mandl EW, Kops N, Koevoet WJ, Verhaar JA, Van Osch GJ. An osteochondral culture model to study mechanisms involved in articular cartilage repair. Tissue Eng Part C Methods 2012;18(1):45–53.
[8] Bos PK. Articular cartilage repair and the evolving role of regenerative medicine. Open Access Surg 2010:109;3:109-122.
[9] Van Osch GJVM, Brittberg M, Dennis JE, Bastiaansen-Jenniskens YM, Erben RG, Konttinen YT, Luyten FP. Cartilage repair: past and future - lessons for regenerative medicine. J Cell Mol Med 2009;13 (5):792–810.
[10] Qi YY, Chen X, Jiang YZ, Cai HX, Wang LL, Song XH, Zou XH, Ouyang HW. Local delivery of autologous platelet in collagen matrix simulated in situ articular cartilage repair. Cell Transplant 2009;18(10):1161–1169.

Downloaded by [University Town Library of Shenzhen] at 20:50 14 December 2017

[11] Giannini S, Buda R, Battaglia M, Cavallo M, Ruffilli A, Ramponi L, Pagliazzi G, Vannini F. One-step repair in talar osteochondral lesions: 4-year clinical results and t2-mapping capability in outcome prediction. Am J Sports Med 2013;41(3):511–518.

[12] Guney A, Akar M, Karaman I, Oner M, Guney B. Clinical outcomes of platelet rich plasma (PRP) as an adjunct to microfracture surgery in osteochondral lesions of the talus. Knee Surg Sports Traumatol Arthrosc 2015;23(8):2384–2389.

[13] Fortier LA, Barker JU, Strauss EJ, McCarrel TM, Cole BJ. The role of growth factors in cartilage repair. Clin Orthop Relat Res 2011;469(10):2706–2715.

[14] Sun Y, Feng Y, Zhang CQ, Chen SB, Cheng XG. The regenerative effect of platelet-rich plasma on healing in large osteochondral defects. Int Orthop 2010;34(4):589–597.

[15] Smyth NA, Murawski CD, Fortier LA, Cole BJ, Kennedy JG. Platelet-rich plasma in the pathologic processes of cartilage: review of basic science evidence. Arthroscopy 2013;29 (8):1399–1409.

[16] Zhu Y, Yuan M, Meng HY, Wang AY, Guo QY, Wang Y, Peng J. Basic science and clinical application of platelet-rich plasma for cartilage defects and osteoarthritis: a review. Osteoarthritis Cartilage 2013;21(11):1627–1637.

[17] Ghanaati S, Booms P, Orlowska A, Kubesch A, Lorenz J, Rutkowski J, Landes C, Sader R, Kirkpatrick C, Choukroun J. Advanced platelet-rich fibrin: a new concept for cell-based tissue engineering by means of inflammatory cells. J Oral Implantol 2014;40(6):679–689.

[18] Choukroun J, Ghanaati S. Reduction of relative centrifugation force within injectable platelet-rich-fibrin (PRF) concentrates advances patients' own inflammatory cells, platelets and growth factors: the first introduction to the low speed centrifugation concept. Eur J Trauma Emerg Surg 2017.

[19] El Bagdadi K, Kubesch A, Yu X, Al-Maawi S, Orlowska A, Dias A, Booms P, Dohle E, Sader R, Kirkpatrick CJ, et al. Reduction of relative centrifugal forces increases growth factor release within solid platelet-rich-fibrin (PRF)-based matrices: a proof of concept of LSCC (low speed centrifugation concept). Eur J Trauma Emerg Surg 2017;28(12):188

[20] Miron RJ, Fujioka-Kobayashi M, Hernandez M, Kandalam U, Zhang Y, Ghanaati S, Choukroun J. Injectable platelet rich fibrin (i-PRF): opportunities in regenerative dentistry?. Clin Oral Investig 2017;21(8):2619–2627.

[21] Wang X, Zhang Y, Choukroun J, Ghanaati S, Miron RJ. Effects of an injectable platelet-rich fibrin on osteoblast behavior and bone tissue formation in comparison to platelet-rich plasma. Platelets 2017:1–8.

[22] Fujioka-Kobayashi M, Miron RJ, Hernandez M, Kandalam U, Zhang Y, Choukroun J. Optimized Platelet-Rich Fibrin With the Low-Speed Concept: growth Factor Release, Biocompatibility, and Cellular Response. J Periodontol 2017;88(1):112–121.

[23] Miron RJ, Hedbom E, Saulacic N, Zhang Y, Sculean A, Bosshardt DD, Buser D. Osteogenic potential of autogenous bone grafts harvested with four different surgical techniques. J Dent Res 2011;90 (12):1428–1433.

[24] Zhang Y, Wei L, Miron RJ, Shi B, Bian Z. Anabolic Bone Formation Via a Site Specific Bone Targeting Delivery System by Interfering with Semaphorin 4D Expression. J Bone Miner Res 2015;30(2):286–96.

[25] Smyth NA, Haleem AM, Ross KA, Hannon CP, Murawski CD, Do HT, Kennedy JG. Platelet-Rich Plasma May Improve Osteochondral Donor Site Healing in a Rabbit Model. Cartilage 2016;7(1):104–111.

[26] Matsuda H, Kitamura N, Kurokawa T, Arakaki K, Gong JP, Kanaya F, Yasuda K. Influence of the gel thickness on in vivo hyaline cartilage regeneration induced by double-network gel implanted at the bottom of a large osteochondral defect: short-term results. BMC Musculoskeletal Disorders 2013;14(1):50.

[27] Boopalan PR, Sathishkumar S, Kumar S, Chittaranjan S. Rabbit articular cartilage defects treated by allogenic chondrocyte transplantation. Int Orthop 2006;30(5):357–361.

[28] Nikolidakis DJJ. biology of platelet-rich plasma and its application in oral surgery: literature review. Tissue Eng Part B Rev 2008. 14;249–258.

[29] Marx RE. Platelet-rich plasma: evidence to support its use. J Oral Maxillofac Surg 2004;62(4):489–496.

[30] Freyria AM, Mallein-Gerin F. Chondrocytes or adult stem cells for cartilage repair: the indisputable role of growth factors. Injury 2012;43(3):259–265.

[31] Milano G, Sanna Passino E, Deriu L, Careddu G, Manunta L, Manunta A, Saccomanno MF, Fabbriciani C. The effect of platelet rich plasma combined with microfractures on the treatment of chondral defects: an experimental study in a sheep model. Osteoarthritis Cartilage 2010;18(7):971–980.

[32] Foster TE, Puskas BL, Mandelbaum BR, Gerhardt MB, Rodeo SA. Platelet-rich plasma: from basic science to clinical applications. Am J Sports Med 2009;37(11):2259–2272.

[33] Wu W, Chen F, Liu Y, Ma Q, Mao T. Autologous injectable tissue-engineered cartilage by using platelet-rich plasma: experimental study in a rabbit model. J Oral Maxillofac Surg 2007;65(10):1951–1957.

[34] Miron RJ, Zucchelli G, Pikos MA, Salama M, Lee S, Guillemette V, Fujioka-Kobayashi M, Bishara M, Zhang Y. Wang HL and others. Use of platelet-rich fibrin in regenerative dentistry: a systematic review. Clin Oral Investig 2017;21(6):1913–1927.

[35] Choukroun J, Diss A, Simonpieri A, Girard MO, Schoeffler C, Dohan SL, Dohan AJ, Mouhyi J, Dohan DM. Platelet-rich fibrin (PRF): a second-generation platelet concentrate. Part IV: clinical effects on tissue healing. Oral Surg Oral Med Oral Pathol Oral Radiol Endod 2006;101(3):e56–60.

[36] Dohan DM, Choukroun J, Diss A, Dohan SL, Dohan AJ, Mouhyi J, Gogly B. Platelet-rich fibrin (PRF): a second-generation platelet concentrate. Part I: technological concepts and evolution. Oral Surg Oral Med Oral Pathol Oral Radiol Endod 2006;101(3):e37–44.

[37] Haleem AM, Singergy AA, Sabry D, Atta HM, Rashed LA, Chu CR, El Shewy MT, Azzam A, Abdel Aziz MT. The Clinical Use of Human Culture-Expanded Autologous Bone Marrow Mesenchymal Stem Cells Transplanted on Platelet-Rich Fibrin Glue in the Treatment of Articular Cartilage Defects: A Pilot Study and Preliminary Results. Cartilage 2010;1(4):253–261.

[38] Evans CH, Palmer GD, Pascher A, Porter R, Kwong FN, Gouze E, Gouze JN, Liu F, Steinert A. Betz O and others. Facilitated endogenous repair: making tissue engineering simple, practical, and economical. Tissue Eng 2007;13(8):1987–1993.

[39] Qiu YS, Shahgaldi BF, Revell WJ, Heatley FW. Observations of subchondral plate advancement during osteochondral repair: a histomorphometric and mechanical study in the rabbit femoral condyle. Osteoarthritis Cartilage 2003;11(11):810–820.

[40] Wang X, Zhang Y, Choukroun J, Ghanaati S, Miron RJ. Behavior of Gingival Fibroblasts on Titanium Implant Surfaces in Combination with either Injectable-PRF or PRP. Int J Mol Sci 2017. 18;2.

[41] Perut F, Filardo G, Mariani E, Cenacchi A, Pratelli L, Devescovi V, Kon E, Marcacci M, Facchini A. Baldini N and others. Preparation method and growth factor content of platelet concentrate influence the osteogenic differentiation of bone marrow stromal cells. Cytotherapy 2013;15(7):830–839.

[42] Pirraco RP, Reis RL, Marques AP. Effect of monocytes/macrophages on the early osteogenic differentiation of hBMSCs. J Tissue Eng Regen Med 2013;7(5):392–400.

[43] Kawazoe T, Kim HH. Tissue augmentation by white blood cell-containing platelet-rich plasma. Cell Transplant 2012;21(2–3):601–607.

[44] Kobayashi E, Fluckiger L, Fujioka-Kobayashi M, Sawada K, Sculean A, Schaller B, Miron RJ. Comparative release of growth factors from PRP, PRF, and advanced-PRF. Clin Oral Investig 2016;20(9):2353–2360.

View publication stats